


PATIENT

Abby Das

PRESENTING CLINICAL SIGNS

 History: Recheck echo. Assess prior to anesthesia for a TPLO.
 -Current medications: Vetmedin, Enalapril, Furosemide, Gabapentin, Tramadol.
 -CXR: Showed cardiomegaly.

SPECIES

Canine

-Pertinent previous echo findings (3/2021 MML): Moderate MR, moderate LAE, mild LVE, trace TR. LA: 2.3, LA/AO: 1.8, LV: 3.5.

BREED

Cocker Mix

SEX

Femal Spayed

AGE

13 years

ECHOCARDIOGRAM FINDINGS

2D, m-mode, color flow and doppler imaging is available. Diffuse thickening of mitral valve leaflets (anterior>posterior) with minimal prolapse into the left atrial lumen. Moderate eccentric mitral regurgitation with moderate left atrial dilation. Normal MR velocity. Mildly increased LV diameter with hyperdynamic myocardial function. The tricuspid valve appears subjectively normal, with trace tricuspid regurgitation. Normal velocity. Normal right atrial and ventricular diameter. The pulmonic and aortic valves are normal in morphology and mobility. Normal pulmonic and aortic outflow velocities. No aortic or pulmonic insufficiency. No pericardial or pleural effusion noted. No cardiac tumors observed.

CARDIAC CHART
WEIGHT

25.4lbs

INTERPRETED BY

 Maggie Machen Lamy,
 DVM DACVIM
 (Cardiology)

IMAGING PERFORMED BY

Kelly Reschny, RVT

HOSPITAL NAME

 College Animal
 Hospital

REFERRING VET

Dr. Hanna

CANINE CARDIAC PARAMETERS	MR VMAX (m/s)	TR VMAX (m/s)	LA/AO (Boon method)	LA/AO (Heart Base; Swe)	FS (%)	EF (%)	EPSS (cm)
NORMAL PARAMETER	4.5-5.5	<2.7	1.3	<1.6	28-40	40-100	<0.6
PATIENT	>7.0	2.0	NM	1.8	34	65	0.3
CANINE CARDIAC PARAMETERS	HR (BPM)	AV VMAX (m/s)	PV MAX (m/s)	BODY WEIGHT (kg)	LA 2D short axis Base view (cm)	LVIDd Avg; 2D and m-mode short axis (cm)	LVIDs Avg; 2D and m-mode short axis (cm)
NORMAL PARAMETER	50-100	0.7-1.7	0.7-1.6	BELOW	BELOW	BELOW	BELOW
PATIENT	158	2.5	1.6	11.5	2.9	4.0	2.4
*Normal chamber parameters expressed as a mean value (SD)				3	1.27 (5.3)	2.46 (2.46)	1.36 (5.5)
BODY WEIGHT DEPENDENT PARAMETERS				5	1.40 (4.5)	2.74 (5.2)	1.60 (4.7)
*Note: All measurements based upon multi-modal images and methods. An average value is reported.				10	1.50 (3.8)	3.27 (3.5)	2.06 (3.1)
				15	1.83 (2.0)	3.71 (2.4)	2.43 (2.1)
				20	2.02 (1.9)	4.14 (2.2)	2.80 (2.0)
				25	2.18 (2.4)	4.48 (2.9)	3.10 (2.5)
				30	2.33 (3.3)	4.83 (3.9)	3.39 (3.4)
				35	2.48 (4.3)	5.17 (5.0)	3.69 (4.5)
				40	2.62 (5.2)	5.48 (6.1)	3.96 (5.4)
				50	2.88 (7.1)	6.07 (8.3)	4.46 (7.4)

INTERPRETATION OF THE FINDINGS & FURTHER RECOMMENDATIONS

Chronic degenerative valve disease persists with evidence of mild progression. Moderate mitral and trace tricuspid regurgitation are unchanged; however, both the LA and LV are increased comparatively. The disease remains within the moderate category; however, there may be risk for progression to CHF in the future. No obvious additional issues are identified.

INVOICE

27780

DATE

12/2/22



PATIENT

Abby Das

Given these findings, reasonable to continue Pimobendan and Enalapril lifelong as prescribed. No indication for Lasix prior to CHF and this can be discontinued, unless the history dictates otherwise. Continued assessment of progression is recommended, with a guarded prognosis (stage B2). Patient may be at risk for development of CHF, arrhythmias, and/or sudden death going forward.

SPECIES

Canine

Omega fatty acid supplementation and mild salt restriction may also be of some long-term benefit. Monitor for development of a progressive cough, labored breathing, exercise intolerance or collapse episodes.

BREED

Cocker Mix

SEX

Femal Spayed

Anesthetic risk remains moderately elevated. Cardiac protective drug choices (opioid/benzodiazepine premedication, Propofol or alfaxalone induction, iso or sevo gas) are recommended. Monitor for arrhythmias, hypotension, and hypoxia both intra and post-operatively and intervene as necessary. Judicious IV fluid rates are recommended to avoid fluid overload. Avoid heart rate stimulating drugs such as atropine unless clinically indicated.

AGE

13 years

PLAN

Baseline BP recommended every 6 months. Continue Pimobendan 0.25-0.3mg/kg PO q12h. Continue ACE-I 0.5mg/kg PO q12h. Unless CHF has been documented, Lasix can be discontinued.

WEIGHT

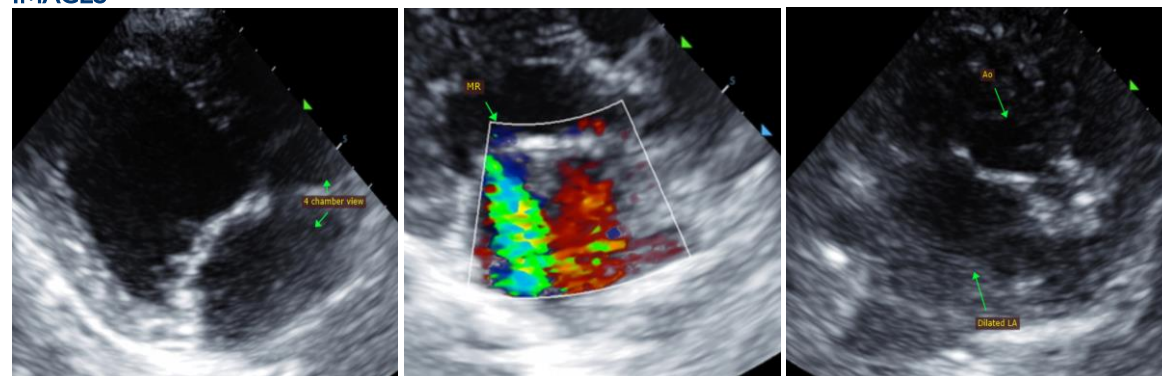
25.4lbs

Recommend monitor for progression with a recheck echocardiogram in 6 months, sooner if any development of clinical signs.

INTERPRETED BY

Maggie Machen Lamy,
DVM DACVIM
(Cardiology)

IMAGES



IMAGING PERFORMED BY

Kelly Reschny, RVT

HOSPITAL NAME

College Animal
Hospital

REFERRING VET

Dr. Hanna

The information and recommendations provided are based on the images presented by the referring veterinarian. No evaluation can be communicated regarding pathology that was not visible in the image/video clips provided.

Thank you for this referral. This report was generated using transcription software, and minor dictation errors may be present. If the clinical or image interpretation does not parallel your findings or if I can be of any further assistance, please contact me.

INVOICE

27780

DATE

12/2/22

Maggie Machen Lamy, DVM

Diplomate of the American College of Veterinary Internal Medicine (Cardiology)

info@sonopath.com